

Image Based Grading of Emphysema

Nishi Shahnaj Haider, Sibin Thomas, Akhilesh Kumar Shrivastava



Abstract: Emphysema is permanent abnormal enlargement of alveolar walls due to destruction of the alveolar tissues and thereby affecting the gas exchange process of lungs. Grading is usually done to rank the severity of the disease. This paper is a comprehensive review of the imaging based methods used to monitor the emphysema severity. This article aims at the identification of the best imaging method for emphysema grading. Correlation of imaging outcome with pulmonary function parameters is analyzed. Time frame of reviewed articles included is from 2002 to till date. In this review, the classification methods employed for grading emphysema are examined. The best grading method was chosen based on the superior performance obtained in comparison to all the existing work available so far in grading the severity of emphysema. Three-dimensional CT densitometry is found to be highly significant with a correlation coefficient of $r = 0.97$ at significance value, $p < 0.001$ for the classification of moderate to very severe emphysema as compared to pulmonary function test (PFT). Further research needs to be done to identify methods for evaluating the progress of emphysema during its mild stage.

Keywords: Chronic Obstructive Pulmonary Disease, disease severity, emphysema, grading, imaging.

I. INTRODUCTION

Chronic Obstructive Pulmonary Disease (COPD) is a group of disease which causes the parenchymal destruction (emphysema) and airway obstruction (bronchitis and bronchiolitis) [1]. It is a biggest health burden globally. It is currently the fourth major cause of mortality and it is expected to reach third position by 2030 [2]. It causes non-reversible respiratory function impairment [3]. As per the American Thoracic society, emphysema is abnormal and permanent enlargement of alveolar walls which occurs due to destruction of the alveolar tissue and thereby, deteriorating the gas exchange process inside the lungs [1]. Collagen fibers of lungs, withstands the mechanical load during respiration which protects lungs from damage. However, the exposure of smoke and toxic gases stimulates interstitial collagenases which directly damage them. Mass destruction of collagen fibers damages the small airways and deteriorates the exchange of oxygen and carbon dioxide, leading to emphysema [4]. Exposure to smoke, pollutants, or smoking habits are some of the causes of emphysema [5].

Other factors like genetic predisposition, which causes alpha1 antitrypsin deficiency. Deficiency of alpha1 antitrypsin can also lead to emphysema [6-7]. Sharafkhan et al. [8] have showed that starvation is another reason for emphysema. Still, pathogenesis of emphysema is unclear. Therefore, researchers are taking more interest to explore in this area [9-10]. According to distribution of disease in secondary pulmonary lobules, the emphysema is of three subtypes: centrilobular, panlobular, distal acinar emphysema [11].

Pulmonary function tests (PFT) is a clinical method which is used for monitoring a known respiratory disorder in patient [12]. It can be used to assess the severity of lungs, but detecting a particular breathing disorder is very difficult. Spirometry can be used to observe the air obstruction, but gives no diagnostic confirmation of emphysema [13-14]. Emphysema is a structural and heterogeneous disease. However spirometry result fails to describe the heterogeneity as well as it required the patient's cooperation and efforts, which limited its outcomes [12-14]. Therefore, imaging modalities are the best option for assessing the severity of emphysema [15].

Apart from the disease classification, it is very important to grade the emphysematous lesions, in order to examine the extent and severity level of COPD, which could help the physicians for taking diagnostic decisions [16]. Grading means to rate the severity into different category as mild, moderate, severe and very severe. Early or the beginning stage can be defined as mild emphysema. Lung parenchyma destruction with moderate symptoms called as moderate emphysema. Advanced stage is severe emphysema, whereas very advanced stage is categorized as very severe emphysema [17-18]. Lack of severity monitoring and misdiagnosis could cause disease advancement towards the complete lung failure. Lung volume reduction surgery and lung transplantation are the only option left to save the life of patient with emphysema at very advanced stage. Thus, grading is extremely important for classification of emphysema. Hence, it is required that there should be effective method which could help physicians to accurately monitor the severity progress of emphysema, to evaluate the disease progress. Such diseases progress monitoring may help the physician to choose the right treatment process to cure emphysema in a perfect way in a short period of time. In this review, the entire image based grading methods will be discussed and analyzed.

II. MATERIAL AND METHODS

Grading of emphysema has been a great subject of interest for physicians and researchers for more than 40 years. To examine the existing methods available so far to grade emphysema, the present survey was conducted.

Revised Manuscript Received on June 30, 2020.

* Correspondence Author

Nishi Shahnaj Haider* Department of Biomedical Engineering, Karunya Institute of Technology and Sciences, Coimbatore, Tamil Nadu, India

Sibin Thomas, Department of Computer Science, C V Raman University, Bilaspur, Chhattisgarh, India

Akhilesh Kumar Shrivastava, Department of Computer Science, C V Raman University, Bilaspur, Chhattisgarh, India

© The Authors. Published by Blue Eyes Intelligence Engineering and Sciences Publication (BEIESP). This is an open access article under the CC BY-NC-ND license (<http://creativecommons.org/licenses/by-nc-nd/4.0/>)

Overall 57 papers were selected for this review. This comprehensive review focuses basically on the methods available on severity classification of emphysema.

A. PFT for assessing severity of emphysema.

Pulmonary function testing included three basic components: spirometry, lung volumes, and diffusing capacity of the lung for carbon monoxide (DLCO) [19]. Spirometry included the parameters like forced vital capacity (FVC), forced expiratory volume in one second (FEV₁) and the ratio of forced expiratory volume in one second to forced vital capacity (FEV₁/FVC). According to the Global Initiative for Chronic Obstructive Lung Disease (GOLD) 2017 [20], the severity assessment of airflow obstruction of COPD patients can be done using spirometry as shown in table1.

Other than spirometry, lung volumes could also be quantified to analyze the lung function. Lung volumes consist of: residual volume (RV), total lung capacity (TLC) and functional residual capacity (FRC). Both TLC and RV were found to be increased with COPD progress [19]. FRC also increases with increased severity in COPD patients [21]. Another PFT parameter was diffusing lung capacity for carbon monoxide (DLCO) which decreases with COPD progress[19].

Table1. Classification of severity of airflow limitation in COPD (Based on post-bronchodilator FEV₁) in patients with FEV₁/FVC <0.70

GOLD1	Mild	FEV ₁ ≥80% predicated
GOLD2	Moderate	50%≤FEV ₁ ≥80% predicted
GOLD3	Severe	30%≤FEV ₁ ≥50% predicted
GOLD4	Very severe	FEV ₁ <30% predicted

B. Why imaging based methods for emphysema grading?

As PFT are of limited value for assessing mild stage to moderate stage of emphysema, therefore, imaging based grading methods are more prominent [22]. More researches are undergoing to reduce the cost of imaging and to monitor severity progress of emphysema from mild to very severe. Imaging for grading emphysema is a non-invasive, effortless and comfortable procedure for all age groups. Therefore, imaging based grading is preferred and it could be further explored to do exact staging for severity monitoring of emphysema.

C. Review on methods available for grading of emphysema

Chest x-ray is one of the imaging modality used to examine the prevalence of emphysema. But, chest radiography has failed to identify the mild emphysema [23]. Study suggest that the radiologic findings were in range of excellent to poor for detecting and grading of emphysema using chest radiography [24]. Recently, Dong et al. [25] proposed the diffraction enhanced imaging (DEI) method to detect the early stage from X-Ray images of emphysema. With the help of DEI method, it was possible to detect mild emphysema. Information's like refraction, absorption and ultra-small angle X-ray scattering (USAXS) were retrieved by employing the multiple image radiography (MIR). The

absorption image was combined with USAXS image by a scatter plot. The mild emphysema detection was done with the help of alveolar inflation. The alveolar inflation changes the frequency of tissue microstructure. However, USAXS showed sensitivity towards change of tissue microstructure, with which mild emphysema detection was done. It was observed that, with the help of this feature, it was easy to visualize the lesions which were hidden in absorption image as shown in figure 1.




Fig 1. a, b, c shows absorption, refraction and USAXS images of emphysema lung, respectively [courtesy Dong et al. [25]]

Computed tomography is one of the efficient imaging technique to diagnose and monitor emphysema. Hence, computed tomographic (CT) imaging is mostly adopted by researchers to quantify and grade emphysema [26]. Recently, Kurugol et al. [27] proposed the multi-class hierarchical approach to classify and grade the monotonic emphysema patterns. The features extracted from image patches were fed as input to the support vector machine (SVM) classifier. In this special structure was followed for emphysema classification, for example, at first node five classes were there and 4 ways to split those classes into subsets. The locations of cut points were from class k-1 to k ({1}, {2, 3, 4, 5}), ({1, 2}, {3, 4, 5}), ({1, 2, 3}, {4, 5}), ({1, 2, 3, 4}, {5}). This approach suppressed the large number of comparisons at every node. The classifier trees were trained and the optimal one was selected on the basis of maximum accuracy criterion. Using this method, emphysema progress was classified as normal, mild, moderate, severe and severe panlobular. According to Dijkstra et al. [28], grading of emphysema could be done by calculation of fifteenth percentile of Hounsfield density distribution of lung volume. Severity staging was done as follows: emphysema and normal lung function (n = 8, p15 > -920HU and % FEV₁/FVC > 85 %), moderate emphysema and normal lung function (n = 4, -940 < p15 < -960HU and FEV₁/FVC > 70 %) and no emphysema and severe airflow limitation (n = 8, p15 > -920HU and % FEV₁/FVC < 50 %). Liang et al. [29] presented a multilayer perceptron neural network based detection of severity levels of emphysema in the form of 5 classes of severity: class I(normal region), class II(mild), class III(moderate), class IV(severe), and class V(very severe). This neural network (NN) included 23 input nodes, first hidden layer with 30 neurons,

second hidden layer with 20 neurons, third hidden layer with 10 neurons, and output layer with 5 output nodes. Back propagation algorithm was used to train the NN.

Todd et al. [30] presented the modified scale of National Emphysema Treatment Trial (NETT) scoring system. As per this system, the whole lungs were divided into 12 zones. The extent to which the lungs are affected with emphysema were scored as: score 0 (no emphysema); score 0.5 (trivial, < 5%); score 1 (mild, 5% - 25%); score 2 (moderate, 26% - 50%); score 3 (marked, 51% - 75%); and score 4 (severe, > 75%). Irion et al. [31] evaluated the severity of emphysematous lesions using CT densitovolumetry with a threshold of -950HU, is one of the emerging method for characterization of emphysema. This study has found that the healthy young population also showed small emphysematous signs using densitovolumetry at a threshold of -950 HU. Kim et al. [32] showed that the correlation of measures obtained from the CT scan with that of lung function of emphysema patients. Densitometric measure was calculated at a threshold of -950HU and was declared as percent emphysema (%LAA). Subjects observed with higher values of percentage of low attenuation area (% LAA) were expected to have higher degree of parenchymal destruction due to emphysema. Sorensen et al. [33] demonstrated a texture based system for the examine the severity of emphysema. The severity was measured by using pixel posterior probabilities output through a classifier. The severity was differentiated as: healthy, centrilobular emphysema, and paraseptal emphysema. In this, local binary pattern were the texture features. Joint LBP and intensity histograms were used to characterize the region of interest (ROIs). Classification was carried out using k-nearest neighbor (KNN) classifier. For severity assessment, Marcos et al. [34] reported a unique methodology to rank the severity in a particular lung area with respect to its D_2 value. A variable called as severity index (SI) was defined which represented the probability for a emphysematous lung area. The severity index was expressed with regard of parameter D_2 , which is a robust descriptor of pulmonary airspace enlargement. This parameter D_2 associated with the 2nd and 3rd moments of the variable d (diameter), which characterizes size of airspace. The severity evaluation could not be done directly using D_2 . The gap between the airspace enlargement and emphysema severity was controlled with the inclusion of SI function. This study introduced Bayesian approach to develop mapping function to relate D_2 and SI. The degree of severity was categorized as normal $0 < SI < 0.5$; mild $0.5 < SI < 0.7$; and severe $0.7 < SI < 1$.

Magnetic resonance imaging (MRI) is another imaging modality with which analysis of damaged lung function could be analyzed in COPD patients [35]. Beek et al. [36] showed severity assessment of emphysema in MRI images using apparent diffusion coefficients (ADC) and categorize the subjects as normal, mild, moderate and severe. Stavngaard et al. [37] investigated severity progress of emphysema patients with diffusion-weighted hyperpolarized (HP) ^3He magnetic resonance imaging (MRI) using the method of apparent diffusion coefficient (ADC). For analysis, pixels were selected above a certain threshold value. The threshold was taken as $4 * \text{mean}(\text{noise})$ for non-diffusion weighted images while $\text{mean}(\text{noise}) + 2 * \text{std}(\text{noise})$

for diffusion weighted images. The $\text{mean}(\text{noise})$ and $\text{std}(\text{noise})$ were the average and standard deviation of the pixel intensities in a noise region outside the lungs. Global ADC was determined as the average ADC of the three coronal slices. This study indicated some association between ADC and FEV_1 . Therefore, non-radiation HP ^3He MRI could be further explored to assess severity progress of emphysema.

High resolution computed tomography (HRCT) is more sensitive to detect and characterize emphysema compared to chest radiography [38]. Beek et al. [36] also demonstrated mean lung density (MLD) method to categorize the severity of emphysematous lesions of HRCT images. The outcomes were observed to be positively correlated with $\% \text{FEV}_1 / \text{FVC}$. Parr et al. [38] showed the assessment of lung densitometry parameters such as 15th percentile point and voxel index (VI) for evaluation of emphysema severity. Both the parameters decrease with increase of emphysema severity. Hersh et al. [39] proposed emphysema severity scoring of HRCT images using modification of National Emphysema Treatment Trial (NETT). This assessment was done by three thoracic radiologist and pulmonary physicians. In this scoring system, a score was assigned from 0 to 4 for the upper, middle and lower portion of lungs: normal-none; trivial(less than 5% affected)-0.5, mild (5-25% affected)-1; moderate (26-50% affected)-2; marked (51-75% affected); severe (>75% affected). Charemza et al. [40] demonstrated integral geometry descriptors to characterize emphysema in HRCT images using minkowski functional. These functions were calculated employing lung data threshold at -600 HU with the voxel regions of $6 \times 6 \times 4$ size. Principal component analysis was performed for visualization of the output data, and thus to obtain color descriptors. Based on colored descriptors, normal tissues were viewed as green, emphysema/fibrosis as blue, etc. Prasad et al. [41] introduced an automated texture based system which was able to do multi level classification of emphysema. This study put forward a system, which was named as Inc_MVL, which was an advanced version of Meta_MVL. The images labeled by the experts were incorporated incrementally to raise the system performance. Meta_MVL was able to classify from the just bullous regions of lungs in terms of larger set of diffuse and bullous areas present inside the lungs. Inc_MVL was able to detect diffuse areas from bullous regions. This approach was entirely based on multi-view learning. A heuristic based filter was used to reduce the errors while labeling diffuse areas of emphysema. Wang et al. [42] assessed HRCT variables like mean lung density, 15th percentile (Perc15), percentage of relative area having attenuation values < -950HU (RA950), histogram analysis for grading emphysema. The relative area (RA950) below -950HU showed better significant value of correlation with FEV_1 compared to other parameters ($r=0.71$ & $p<0.001$).

Dual-energy computed tomographic pulmonary angiography (DE-CTPA) is a modality which eases the simultaneous analysis of parenchymal density, lung morphology and lung perfused blood volume [43].

Meinel et al. [43] quantified the lung perfused blood volume (PBV) of emphysema patients.

PBV was quantified with the measurement of enhancement values of pulmonary parenchyma with respect to reference vessel. The PBV was estimated as (mean enhancement of parenchyma/ mean enhancement of pulmonary trunk) /calibration factor 0.15. The obtained PBV values were found correlated with correlation coefficient of $r = 0.67$ at significance value of $p < 0.001$ with respect to lung function parameters.

Single photon emission computer tomography (SPECT) is another imaging modality adopted by researchers to rank the severity degree of emphysema [44]. Nagao and Murase et al. [44] used concept of three-dimensional fractal analysis (3D-FA) for severity assessment of emphysema as shown in figure 2. Fractal dimension represents the information regarding spatial or temporal heterogeneity. Higher values of fractal dimension showed the greater structural complexity. Certain four or five maximal voxel radioactivity cut offs were used to differentiate the organic tissue. The total apparent area of organic tissues was found to be varied with respect to that of radioactivity thresholds. Those thresholds were assumed as per the equation (1)

$$M(\varepsilon) = m \cdot \varepsilon^{-FD} \quad (1)$$

Where m is scaling constant and FD is fractal dimension. Total number of voxel dimension having radioactivity greater than threshold were assumed as $M(\varepsilon)$. This equation indicated that when ε increases then $M(\varepsilon)$ decreases. Hence a linear regression was obtained between $M(\varepsilon)$ and ε . Increase of fractal dimension reflected the more heterogeneous distribution of radionucleoids. Fractal dimensions were calculated for lower portion, upper portion and total lung and were represented upper-lung fractal dimension (U-FD) lower-lung fractal dimension (L-FD) and as total-lung fractal dimension (T-FD). These calculated fractal dimensions were used to assess severity of emphysema. T-FD was found strongly correlated in contrast to U-FD and L-FD.

With the emerging advancements on multi detector computer tomography (MDCT) and processing techniques, it is possible to do non-invasive severity assessments of diseases with good accuracy [45]. Xu et al. [46] demonstrated the three dimensional adaptive multiple feature method (3D-AMFM) to discriminate emphysema. AMFM was a texture based method which categorizes emphysema into five different stages: emphysema in patients with severe COPD (EC), mild emphysema in patients with mild COPD (MC), normal appearing lung in subjects with mild COPD (NC), normal lung with normal lung function in non-smokers (NN), and normal lung in normal smokers (NS). In this method, training images were firstly selected. The volume of interest (VOI's) on the images were identified by experienced observers and VOI's were processed to remove those voxels reflecting the airways or blood vessels. Feature selection was carried out using a suitable feature selection algorithm. Finally, Bayesian classifier was used to discriminate the tissue classes. Recently, Atta et al. [47] demonstrated the quantitative validation of MDCT with 3D CT densitometry to detect the severity of emphysema. Voxels having attenuation value of -950HU were considered as the

threshold for predicting the severity of emphysema. However the percentage of low attenuation area (%LAA) provides the total low attenuation volume. Therefore, excellent correlation was observed in between low attenuation volume with respect to PFT outcomes. Hassan and Elhamd et al. [48] have proposed picture-grading system to assess the severity levels of emphysema on the basis of 0 to 100 scoring system. Severity grading was done based on the severity score as follows: (score ≤ 5) trace; (score 10-30) mild; ($50 \leq \text{score} < 30$) moderate; and (score > 50) severe. Weilputz et al. [49] has showed non-invasive characterization of emphysema using density mask analysis. Emphysema index (EI) was estimated by calculating low attenuation volumes below a threshold of -950HU. However, the calculated EI has showed moderate degree of correlation with PFT values. Therefore, overall this section shows the important basis for research on various image based grading methods and its correlation with radiologic/pathologic to detect the severity of emphysema. Hwang et al. [50], demonstrated that the complexity of lungs could be directly estimated with fractal dimension power-law exponents (D). It was found that there was close association between the size of emphysematous holes and power law exponent (D). This study developed a methodology to quantify the size of emphysematous holes, which they further applied for estimating D . It was observed that D was robust towards breath-hold variations and shows sensitivity towards severity of emphysema. Bae et al. [51] classified the severity using emphysema ratio. Emphysema ratio was calculated as the percentage ratio between lung volume and emphysema volume. It showed negative association with FEV1 and FEV1/FVC. Rezk et al. [52] proposed the 3D volumetry at a threshold of -900HU to assess severity stage of emphysema. In this study, firstly the volume of each lung was calculated with the manual tracing technique. The emphysematous components volume was determined for both the lung. Then, -900HU and -950HU thresholds were evaluated and out of them -900HU thresholds were found to be more accurate and produced significant correlation with PFT results.

Hoesein et al. [53] demonstrated the association in between the airway wall thickness and with the deterioration of lung function in emphysema patient. Accurate lumen and wall borders were examined using intensity orientation technique. The lumen perimeter and wall area were calculated for each cross-section.

Air wall thickness was evaluated with that of the square root of the wall area of 10mm lumen perimeter (P_{10}). In addition to this, Hoesein et al. [53] also investigated the 15th percentile method (Perc15) to determine the severity stage of emphysema. This method involved the determination of those Hounsfield points under which 15% voxels were distributed. The Perc15 was adjusted by multiplication of Perc15 with that of CT total lung volume and divided by predicted value of total lung capacity. ¹³³Xe ventilation imaging is another non-invasive imaging which is adopted to monitor the progress of emphysema [54]. Mathews et al. [54]

investigated the tendency of quantitative gas trapping index (GTI) obtained from ^{133}Xe ventilation scan to monitor the severity progress of emphysema.

For calculating GTI, the equilibrium-phase image having the maximum total counts was selected as reference frame. This image was split into 6 zones. The quantitative analysis was done using rectangular ROI. The washout phase for each image was determined followed by computation of ROI of each washout images. Finally, the GTI was determined as the percentage of gas trapped in the three minute washout images.

Positron emission tomography is one of the non-invasive molecular imaging which can be used to quantify and assess emphysema [55]. Torigian et al. [55] theorized partial volume correction (PVC) to assess the severity of emphysema from the fluoro-18-2-fluoro-2-deoxy-D-glucose positron emission tomography (18F-FDG-PET) scans. From the PET images, lung uncorrected maximum SUV (USUVmax) was manually measured. To evaluate the degree of emphysematous lungs, a 1st level of PVC of lung USUVmax was calculated as in equation (2).

$$\text{CSUVmax} = \text{USUVmax} / (1 - \text{Fr}) \quad (2)$$

Where, (1-Fr) reflects the non-emphysematous part of lung. The 2nd level of PVC of non-emphysematous lung SUVmax to estimate the both the lung parenchymal as well as air portion was evaluated as shown in equation (3).

$$\text{CCSUVmax} = \text{CSUVmax} / (M + 1000 / 1040) \quad (3)$$

Where, it was assumed that attenuation of air was -1000HU and lung parenchyma was -40HU. 'M' was average mean attenuation of non-emphysematous lung parenchyma. 'Fr' was obtained as fraction of emphysema volume (E) (in cm³) based on a -910HU threshold to the emphysematous lung volume (L) (in cm³). It was found that CSUVmax ($r=0.4660$, $p<0.0001$) and CCSUVmax ($r=0.5479$, $p<0.0001$), were showed a positive degree of correlation with F. Therefore, it was concluded that 18F-FDG-PET/CT could be used to assess the severity of emphysema 18F-FDG uptake is corrected for the partial volume effect.

emphysema with fractal dimension of entire lungs was 0.79.C: 63year old male having severe emphysema with fractal dimension of entire lungs was 2.54[courtesy Nagao et al. [44]].

III. RESULTS AND DISCUSSION

The methodology and the performance of each articles were deeply reviewed. All the available literatures have confirmed their studies outcome by correlating the imaging parameters against the clinical parameters like pulmonary function parameters. The performance of grading method was evaluated by comparing the results with accepted GOLD standard- namely FEV1.

The reviewed methods were correlated with PFT parameters like FEV₁, FVC and FEV₁/FVC. Such comparison is done by correlating the imaging outcomes with PFT data, which indirectly reflects the severity of emphysema. Such performance evaluation has been described in the included literatures. Table 2 clearly indicates the performance of each article in terms of the significance value. It is observed that three-dimensional CT densitometry has shown an excellent statistical correlation ($r = 0.97$ & $p < 0.001$) between the total lung volume and PFT, but mild stage was not detected. In this study, Lungs were segmented from nearby organs, airways and individual lobes. % LAA was calculated which contributed for calculation of total lung volume.

A strong association was observed in between the total lung volume and pulmonary function tests results [47]. From this review, three-dimensional CT densitometry shows significant ($p < 0.001$ & $r = 0.97$) outcomes in contrast to all existing methods as shown in table 2. Overall, three-dimensional CT densitometry is the better method to grade the emphysema from moderate to very severe only. Still further research work needs to be done for detection of emphysema during mild stage. After examining all the existing studies, it has been obtained that more research is needed to detect emphysema during its mild stage.

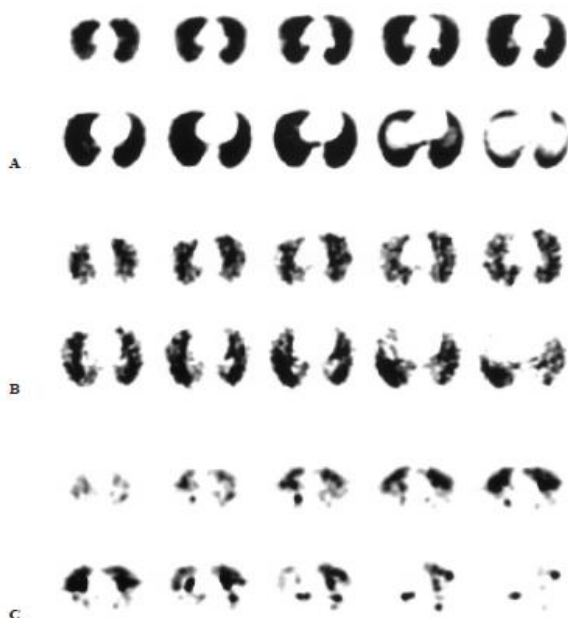

Fig.2. A: 45 year old healthy subject with fractal dimension 0.46. B: 65 year old male patient having mild

Image Based Grading of Emphysema

Table.2.a. Image based methods for severity assessment of emphysema

S N	Imaging modality	First author	Data set	Grading method	Limitation	Significance value
1	Chest X-Ray	Dong[25]	46 images	Diffraction enhanced imaging method	Only early stage detection was shown. Not correlated with any standard outcomes	-
2	CT imaging	Kurugol [27]	1161 image patches	H-SVM classifier	Not correlated with any standard outcomes	-
		Dijkstra [28]	500 subjects	Fifteenth percentile	Outcome is not enough. Female data were not included in the study	p<0.001, b = 0.204
		Liang [29]	3 CT images	Multilayer perceptron neural network	Not correlated with clinical parameters.	-
		Todd [30]	122 COPD subjects	NETT	Validity of result is not confirmed.	p < 0.001
		Irion [31]	30 subjects	Densitovolumetry	Validity of result is not confirmed.	-
		Kim [32]	338 subjects	%LAA	Further investigation is needed	r=-0.07,p= 0.1
				WT		r=-0.12,p=0.03
				SRWA		r=-0.09,p =0.09
		Sorensen [33]	39 subjects	Texture based classification	Patients with mild COPD were not included in this study	r=0.79
		Marcos [34]	66 lung sections	Bayesian approach	Result is not validated.. Moderate emphysema is not examined	-
3	MRI	Beek [36]	122 COPD subjects	Apparent diffusion coefficients	Measurements were less reproducible.	r=0.5
		Stavngaard [37]	Nine patients	Apparent diffusion coefficients	Result was not enough. Less no. of data was used.	r=-0.207
4	HRCT	Beek [36]	122 COPD subjects	Mean lung density	Moderate performance	r=0.52
		Parr [38]	74subjects	Fifteenth percentile Voxel index	Moderate performance	r= 0.527,p = 0.001 r= -0.398p=0.012,
		Hersh [39]	30 emphysema patients	Modified National Emphysema Treatment Trial (NETT)	Average result was obtained.	r=-0.35 to -0.49
		Charemza [40]	One binary image	Minkowski functional	Not correlated with any standard outcomes	-
		Prasad [41]	12 HRCT scans	Meta-classifier	Not correlated with any standard outcomes	-
		Wang [42]	92patients	Relative area below threshold - 950HU (RA950)	Effect of comorbidities was not included.	r=0.71, p<0.001

Table.2.b. Image based methods for severity assessment of emphysema

S	Imaging modality	First author	Data set	Grading method	Limitation	Significance value
5	DE-CTPA	Meinel [43]	40 consecutive patients	Lung perfused blood volume (PBV)	Unfit for direct assessment of pulmonary ventilation	$r = 0.67$; $p < 0.001$
6	SPECT	Nagao and Murase [44]	25 patients (22 males & 3 females)	Three-dimensional fractal analysis	Result was not clearly mentioned. Less female data were included.	-
7	MDCT	Xu [46]	34 subjects	3D Adaptive multiple feature method	Moderate emphysema was not classified. Not correlated with clinical data	-
		Atta [47]	63 COPD patients	3D CT densitometry	Early stage detection was not done.	$r = 0.97$, $p < 0.001$
		Hassan & Elhamd [48]	165 COPD subjects	Picture-grading method	Moderate outcome	$r = 0.542$, $p = 0.003$
		Weilputz [49]	41 Emphysema patients, 21 control	Emphysema index (EI)	Severe patients were not included in study.	$r = -0.66$, $p < 0.007$
		Hwang [50]	100 patients (97 male & 3 female)	Fractal dimension power-law exponents	Result was not sufficient. Less number of female included in the study	$r = 0.4$, $p < 0.0001$
		Bae [51]	74 males and 4 females	Emphysema ratio	Less number of female subjects included in this study.	$r = -0.30$, $p = 0.01$
		Rezk [52]	14 ex-smoker male patients with COPD	Volumetry in -900 HU	Small number of study population. No female included in this study.	$r = 0.476$ & $p = 0.001$
		Hoesein [53]	2021 subjects male smokers	Lumen perimeter (Pi10) 15 th Percentile	No female were included in the study.	$r = -0.49$ & $p < 0.001$ $r = 0.11$ & $p < 0.001$
8	¹³³ Xe ventilation	Mathew [54]	36 patients (22 men, 14 women)	Gas trapping index (GTI)	Study was only conducted on subjects with severe emphysema. The results were not validated.	-
9	PET	Torigian [55]	Forty nine subjects total (35 men and 14 women)	Partial volume correction (PVC)	No correlation against clinical parameter. Less female data were included in contrast to male.	-

IV. CONCLUSION AND FUTURE WORK

Emphysema grading is of great importance. It can help to monitor the severity progress to ease the therapeutics. Overall 50 papers were selected for the review. Each of the existing work is deeply reviewed and evaluated to identify the best method to grade emphysema. As a result of this survey, three dimensional CT densitometry is found to be highly significant for severity assessment of moderate to very-severe emphysema. Relevant work is still not available in assessment of mild emphysema. Diagnosis of emphysema during its mild stage itself can contribute in providing timely treatment and to prevent the disease progress. Future research work will be focused on diagnosing the mild emphysema.

ACKNOWLEDGEMENT

This is declared that the submitted manuscript titled "Image Based Grading of Emphysema" has received no external funding regarding publication of this article.

REFERENCES

1. M.P. Hosseini, H. Soltanian-Zadeh, S. Akhlaghpour, "Detection and severity scoring of chronic obstructive pulmonary disease using volumetric analysis of lung CT images", *Iranian Journal of Radiology*, 2012 Mar; Vol. 9, No. 1, 2012.
2. D. Adeloye, S. Chua, C. Lee, C. Basquill, A. Papan, E. Theodoratou, H. Nair, D. Gasevic, D. Sridhar, H. Campbell, K.Y. Chan, "Global and regional estimates of COPD prevalence: Systematic review and meta-analysis. *Journal of global health*, Vol. 5, No. 2, 2015.
3. D.M. Mannino, D.M. Homa, L.J. Akinbami, E.S. Ford, S.C. Redd, "Chronic obstructive pulmonary disease surveillance-United States, 1971-2000", *Respiratory care*, Vol. 47, No. 10, 2002.
4. B. Suki, K.R. Lutchen, E.P. Ingenito, "On the progressive nature of emphysema: roles of proteases, inflammation, and mechanical forces", *American journal of respiratory and critical care medicine*, Vol. 168, No. 5, 2003.
5. L. Trupin, G. Earnest, M. San Pedro, J.R. Balmes, M.D. Eisner, E. Yelin, P.P. Katz, P.D. Blanc, "The occupational burden of chronic obstructive pulmonary disease", *European Respiratory Journal*, Vol. 22, No. 3, 2003.
6. J.D. Johnson, W.M. Theurer, "A stepwise approach to the interpretation of pulmonary function tests. *American family physician*" Vol. 89, No. 5, 2014.
7. T. Köhnlein, T. Welte, "Alpha-1 antitrypsin deficiency: pathogenesis, clinical presentation, diagnosis, and treatment", *The American journal of medicine*, Vol. 121, No. 1, 2008.
8. A. Sharafkhan, N.A. Hanania, V. Kim, "Pathogenesis of emphysema: from the bench to the bedside", *Proceedings of the American Thoracic Society*, Vol. 5, No. 4, 2008.
9. O.M. Mets, P.A. De Jong, B. Van Ginneken, H.A. Gietema, J.W. Lammers, "Quantitative computed tomography in COPD: possibilities and limitations", *Lung*, Vol. 190, No. 2, 2012.
10. S.S. Salvi, P.J. Barnes, "Chronic obstructive pulmonary disease in non-smokers", *The lancet*, Vol. 374, No. 9691, 2009.
11. M. Takahashi, J. Fukuoka, N. Nitta, R. Takazakura, Y. Nagatani, Y. Murakami, H. Otani, K. Murata, "Imaging of pulmonary emphysema: a pictorial review", *International journal of chronic obstructive pulmonary disease*, Vol. 3, No. 2, 2008.
12. L.A. Mohsen, E.A. Gawad, M.A. Ibrahim, "CT quantification of emphysema: Is semi-quantitative scoring a reliable enough method?" *The Egyptian Journal of Radiology and Nuclear Medicine*, Vol. 45, No. 3, 2014.

13. B.R. Celli, W.A. MacNee, A.A. Agusti, A. Anzueto, B. Berg, A.S. Buist, P.M. Calverley, N. Chavannes, T. Dillard, B. Fahy, A. Fein, "Standards for the diagnosis and treatment of patients with COPD: a summary of the ATS/ERS position paper", *European Respiratory Journal*, Vol. 23, No. 6, 2004.
14. R. Pellegrino, G. Viegi, V. Brusasco, R.O. Crapo, F. Burgos, R.E. Casaburi, A. Coates, C.P. Van Der Grinten, P. Gustafsson, J. Hankinson, R. Jensen, "Interpretative strategies for lung function tests", *European respiratory journal*, Vol. 26, No. 5, 2005.
15. S. Milne, G.G. King, "Advanced imaging in COPD: insights into pulmonary pathophysiology" *Journal of thoracic disease*, Vol. 6, No. 11, 2014.
16. K.L. Irion, B. Hochegger, E. Marchiori, N.D. Porto, S.D. Baldisserotto, P.R. Santana, "Chest X-ray and computed tomography in the evaluation of pulmonary emphysema.", *J Bras Pneumol*, Vol. 33, No. 6, 2007.
17. D. Litmanovich, P.M. Boiselle, A.A. Bankier, "CT of pulmonary emphysema-current status, challenges, and future directions", *European radiology*, Vol. 19, No. 3, 2009.
18. N. Patel, M. DeCamp, G.J. Criner, "Lung transplantation and lung volume reduction surgery versus lung transplantation in chronic obstructive pulmonary disease", *Proceedings of the American Thoracic Society*, Vol. 5, No.4, 2008.
19. K.L. Bailey, "The importance of the assessment of pulmonary function in COPD", *Medical Clinics*, Vol. 96, No. 4, 2012.
20. C.F. Vogelmeier, G.J. Criner, F.J. Martinez, A. Anzueto, P.J. Barnes, J. Bourbeau, B.R. Celli, R. Chen, M. Decramer, L.M. Fabbri, P. Frith P, "Global strategy for the diagnosis, management, and prevention of chronic obstructive lung disease 2017 report, GOLD executive summary", *American journal of respiratory and critical care medicine*, Vol. 195, No. 5, 2017.
21. A. Ali, M.D. Talag, P. Wilcox, "Clinical physiology of chronic obstructive pulmonary disease",
22. M. Emam, J.R. De La Faverie, N. Gharbi, M.I. El-Gohary, "Characterization of lung's emphysema distribution: Numerical assessment of disease development", *In4th International Conference on New Trends in Information Science and Service Science*, IEEE, 2010, pp. 464-469.
23. M. Miniati, S. Monti, J. Stolk, G. Mirarchi, F. Falaschi, R. Rabinovich, C. Canapini, J. Roca, K.F. Rabe, "Value of chest radiography in phenotyping chronic obstructive pulmonary disease", *European Respiratory Journal*, Vol. 31, No. 3, 2008.
24. K. Sashidhar, M. Gulati, D. Gupta, S. Monga, S. Suri S, "Emphysema in heavy smokers with normal chest radiography: Detection and quantification by HRCT", *Acta radiologica*, Vol. 43, No. 1, 2002.
25. L. Dong, J. Li, W. Jian, L. Zhang, M. Wu, H. Shi, S. Luo, "Emphysema early diagnosis using X-ray diffraction enhanced imaging at synchrotron light source", *Biomedical engineering online*, Vol. 13, No. 1, 2014.
26. H.O. Coxson, R.M. Rogers, "Quantitative computed tomography of chronic obstructive pulmonary disease", *Academic radiology*, Vol. 12, No. 11, 2005.
27. S. Kurugol, G.R. Washko, R.S. Estepar, "Ranking and classification of monotonic emphysema patterns with a multi-class hierarchical approach", *IEEE 11th International Symposium on Biomedical Imaging (ISBI) 2014*, pp. 1031-1034.
28. A.E. Dijkstra, D.S. Postma, N. ten Hacken, J.M. Vonk, M. Oudkerk, P.M. van Ooijen, P. Zanen, F.A. Hoesein, B. van Ginneken, M. Schmidt, H.J. Groen, "Low-dose CT measurements of airway dimensions and emphysema associated with airflow limitation in heavy smokers: a cross sectional study", *Respiratory research*, Vol. 14, No. 1, 2013.
29. T.K. Liang, T. Tanaka, H. Nakamura, A. Ishizaka, "A neural network based computer-aided diagnosis of emphysema using CT lung images", *InSICE Annual Conference 2007*, IEEE, 2007, pp. 703-709.
30. N.W. Todd, J. Jeudy, S. Lavania, T.J. Franks, J.R. Galvin, J. Deepak, E.J. Britt, S.P. Atamas, "Centrilobular emphysema combined with pulmonary fibrosis results in improved survival", *Fibrogenesis & tissue repair*, Vol. 4, No. 1, 2011.
31. K.L. Irion, E. Marchiori, B. Hochegger, N. da Silva Porto, J. da Silva Moreira, C.E. Anselmi, J.A. Holemans, P.O. Irion, "CT quantification of emphysema in young subjects with no recognizable chest disease", *American Journal of Roentgenology*, Vol. 192, No.3, 2009.
32. W.J. Kim, E.K. Silverman, E. Hoffman, G.J. Criner, Z. Mosenifar, F.C. Sciurba, B.J. Make, V. Carey, R.S. Estépar, A. Diaz, J.J. Reilly, "CT metrics of airway disease and emphysema in severe COPD", *Chest*, Vol. 136, No. 2, 2009.
33. L. Sorensen, S.B. Shaker, M. De Bruijne, "Quantitative analysis of pulmonary emphysema using local binary patterns", *IEEE transactions on medical imaging*, Vol. 29, No. 2, 2010.
34. J.V. Marcos, A. Muñoz-Barrutia, C. Ortiz-de-Solórzano, G. Cristóbal, "Quantitative assessment of emphysema severity in histological lung analysis", *Annals of biomedical engineering*, Vol. 43, No. 10, 2015.
35. N. Sverzellati, F. Molinari, T. Pirroni, L. Bonomo, P. Spagnolo, M. Zompatori, "New insights on COPD imaging via CT and MRI", *International journal of chronic obstructive pulmonary disease*, Vol.2, No. 3, 2007.
36. E.J. Van Beek, A.M. Dahmen, T. Stavngaard, K.K. Gast, C.P. Heussel, F. Krummenauer, J. Schmiedeskamp, J.M. Wild, L.V. Søgaard, A.E. Mørbach, L.M. Schreiber, "Hyperpolarised ³He MRI versus HRCT in COPD and normal volunteers: PHIL trial", *European Respiratory Journal*, Vol. 34, No. 6, 2009.
37. T. Stavngaard, L.V. Søgaard, M. Batz, L.M. Schreiber, A. Dirksen, "Progression of emphysema evaluated by MRI using hyperpolarized ³He (hp ³He) measurements in patients with alpha-1-antitrypsin (a1at) deficiency compared with CT and lung function tests", *Acta Radiologica*, Vol. 50, No. 9, 2009.
38. D.G. Parr, B.C. Stoel, J. Stolk, R.A. Stockley, "Validation of computed tomographic lung densitometry for monitoring emphysema in α 1-antitrypsin deficiency", *Thorax*, Vol. 61, No. 6, 2006.
39. C.P. Hersh, G.R. Washko, F.L. Jacobson, R. Gill, R.S. Estepar, J.J. Reilly, E.K. Silverman, "Interobserver variability in the determination of upper lobe-predominant emphysema", *Chest*, Vol. 131, No. 2, 2007.
40. M. Charemza, E. Thönnies, A. Bhalerao, D. Parr, "Integral geometry descriptors for characterizing emphysema and lung fibrosis in HRCT images", *InFirst International Workshop on Pulmonary Image Processing (MICCAI 2008)*, pp. 155-164, 2008.
41. M. Prasad, A. Sowmya, P. Wilson, "Multi-level classification of emphysema in HRCT lung images", *Pattern Analysis and Applications*, Vol. 12, No.1, 2009.
42. J.S. Wang, P.M. Cherng, D.S. Perng, H.S. Lee, S. Wang, "High-resolution computed tomography in assessment of patients with emphysema", *Respiratory care*, Vol. 58, No. 4, 2013.
43. F.G. Meinel, A. Graef, S.F. Thieme, F. Bamberg, F. Schwarz, W.H. Sommer, A.D. Helck, C. Neurohr, M.F. Reiser, T.R. Johnson, "Assessing pulmonary perfusion in emphysema: automated quantification of perfused blood volume in dual-energy CTPA", *Investigative radiology*, Vol. 48, No. 2, 2013.
44. M. Nagao, K. Murase, "Measurement of heterogeneous distribution on Technegas SPECT images by three-dimensional fractal analysis", *Annals of nuclear medicine*, Vol. 16, No. 6, 2002.
45. D.E. Litmanovich, K. Hartwick, M. Silva, A.A. Bankier, "Multidetector computed tomographic imaging in chronic obstructive pulmonary disease: emphysema and airways assessment", *Radiologic Clinics*, Vol. 52, No. 1, 2014.
46. Y. Xu, M. Sonka, G. McLennan, J. Guo, E.A. Hoffman, "MDCT-based 3-D texture classification of emphysema and early smoking related lung pathologies", *IEEE transactions on medical imaging*, Vol. 25, No. 4, 2006.
47. H. Atta, G.S. Seifeldein, A. Rashad, R. Elmorshidy, "Quantitative validation of the severity of emphysema by multi-detector CT", *The Egyptian Journal of Radiology and Nuclear Medicine*, Vol. 46, No. 2, 2015.
48. W.A. Hassan, E. Abo-Elhamd, "Emphysema versus Chronic Bronchitis in COPD: Clinical and Radiologic Characteristics", *Open Journal of Radiology*, 2014..
49. M.O. Wielpütz, O. Weinheimer, M. Eichinger, M. Wiebel, J. Biederer, H.U. Kauczor, C.P. Heußel, M.A. Mall, M. Puderbach, "Pulmonary emphysema in cystic fibrosis detected by densitometry on chest multidetector computed tomography", *PloS one*, Vol. 8, No. 8, 2013.
50. J. Hwang, M. Lee, S.M. Lee, S.Y. Oh, Y.M. Oh, N. Kim, J.B. Seo, "A size-based emphysema severity index: robust to the breath-hold-level variations and correlated with clinical parameters",

International journal of chronic obstructive pulmonary disease, Vol. 11, 2016.

51. K. Bae, K.N. Jeon, S.J. Lee, H.C. Kim HC, J.Y. Ha, S.E. Park, H.J. Baek, B.H. Choi, S.B. Cho, J.I. Moon, "Severity of pulmonary emphysema and lung cancer: analysis using quantitative lobar emphysema scoring. Medicine", Vol. 95, No. 48, 2016.
52. N.A. Rezk, A.M. Elrahman, "Objective quantification of emphysema: Determining best threshold on MDCT 3D volumetry; based on lung function evaluation", Egyptian Journal of Chest Diseases and Tuberculosis, Vol. 63, No. 2, 2014.
53. F.A. Hoesein, P.A. de Jong, J.W. Lammers, W.P. Mali, M. Schmidt, H.J. de Koning, C. van der Aalst, M. Oudkerk, R. Vliegenthart, H.J. Groen, B. van Ginneken, "Airway wall thickness associated with forced expiratory volume in 1 second decline and development of airflow limitation", European Respiratory Journal, Vol. 45, No. 3, 2015.
54. J.J. Mathews, A.H. Maurer, R.M. Steiner, N. Marchetti, G. Criner, J.P. Gaughan, H.O. Coxson, "New ¹³³Xe gas trapping index for quantifying severe emphysema before partial lung volume reduction", Journal of Nuclear Medicine, Vol. 49, No. 5, 2008
55. D.A. Torigian, V. Dam, X. Chen, B. Saboury, J.K. Udupa, A. Rashid, S. Moghadam-Kia, A. Alavi, "In vivo quantification of pulmonary inflammation in relation to emphysema severity via partial volume corrected (18) F-FDG-PET using computer-assisted analysis of diagnostic chest CT", Hellenic journal of nuclear medicine, Vol. 16, No. 1, 2013.

AUTHORS PROFILE



Nishi Shahnaj Haider has completed (full-time) PhD from NIT, Raipur in Biomedical Engineering. She has 6 Years of teaching experience of a private engineering institution. She is presently working as Assistant Professor in Karunya Institute of Technology and Sciences, Coimbatore, Tamil Nadu, India as an Assistant Professor. She has many publications in national and international journals.



Mr. Sibin Thomas received MCA from Sikkim Manipal University, Manipal. He is having total teaching experiences of 14 years. His area of interest is .net technologies. He has published paper in 5 international journals and attended 1 international conference. He is presently pursuing PhD from C V Raman University, Bilaspur, Chhattisgarh, India.



Dr. Akhilesh Kumar Shrivastava, has completed his PhD from C V Raman University in Computer Science and IT. He has total 6 Years of teaching experience. He is presently working as Assistant Professor in Department of Computer Science and Information Technology, C V Raman University, Bilaspur, Chhattisgarh, India.